

Surgical Management of Acute Low Back Pain

Kern Singh, MD

Associate Professor

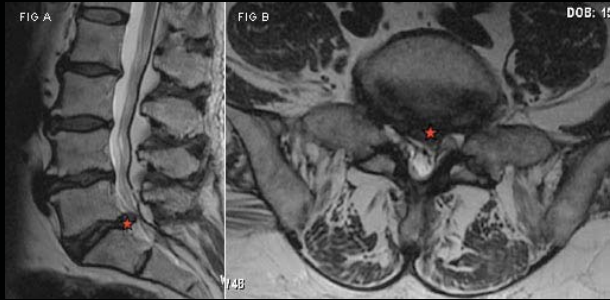
Co-Director, Minimally Invasive Spine Institute

Department of Orthopaedic Surgery

Rush University Medical Center

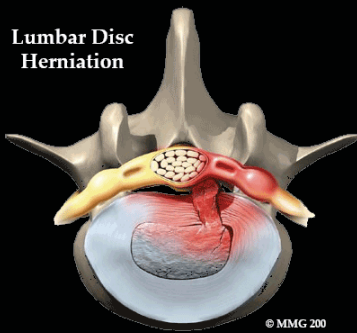
There is none.....

There is none.....



Radiological Report

- Central HNP L5-S1
- Disc height loss L3-4, L4-5
- Disc protrusion L3-4, L4-5



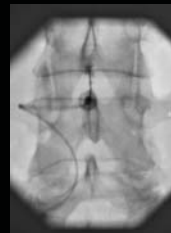
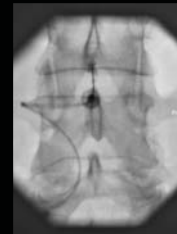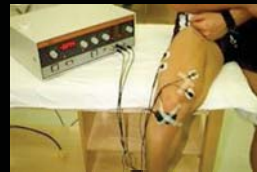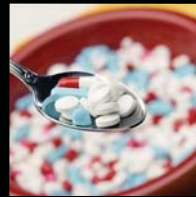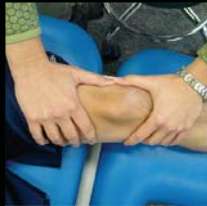Our three patients with the same MRI

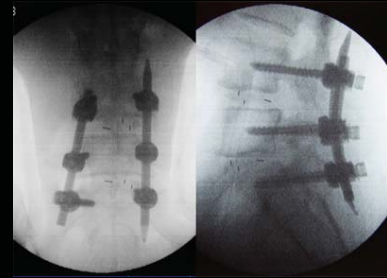
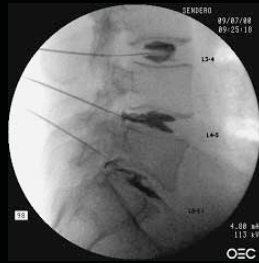

38 yo male
Financial Analyst
Hurt himself playing
basketball

48 yo male
Construction foreman
Hurt himself lifting 30lbs
of 2 x 4's

44 yo female
College Professor
Hurt herself while
running





Lumbar Discogram Report

- Concordant pain
 - L4-5, L5-S1
 - Annular tears L4-5, L5-S1 with dye extravasation.

Two Level Lumbar Fusion

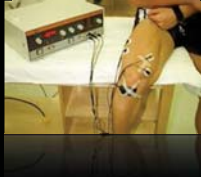

So what went wrong?



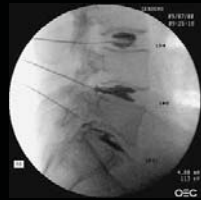Light Duty

High False Positivity

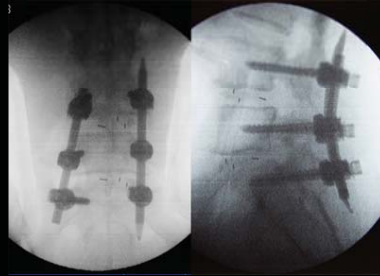


Physical Therapy

High False Positivity



Epidural Injection



Lumbar L5-S1 Microdiskectomy



Random Commentary

Thank You.....

